

TRAUMATIC DISLOCATION OF L4 VERTEBRA, ASSOCIATED WITH PERFORATION OF SMALL INTESTINE AND DISSECTION OF INFRARENAL AORTA: A CASE REPORT AND REVIEW OF LITERATURE

Tihomir Banić¹, Tin Ehrenfreund¹, Damir Halužan¹, Dražen Perković², Goran Pavlek¹, Ivan Dobrić¹, Tonisav Antoljak¹, Tomislav Žigman¹, Daniel Rajačić¹, Tomislav Sečan¹, Dino Bobovec¹, Andreja Prtorić¹

ABSTRACT

Background: A section of the spine most often affected by trauma is located between the T10 and L2 segments. In this paper, we present a patient who suffered injury at the L4–L5 level, as well as dissection of the infrarenal aorta and perforation of the small intestine.

Case study: A 39-year-old woman was injured in a car accident as a passenger, restrained by a seat belt. After resuscitation and diagnostic procedures, the injuries were treated in three stages. First, explorative laparotomy, resection, and T-T anastomosis of the small intestine were done. Repair of infrarenal aorta dissection with the CERAB technique followed. Finally, open reduction and stabilization of the lumbar spine, with exploration of the spinal canal and repair of the dural sac, were performed. In the postoperative period, normal function of the gastrointestinal tract, normal blood flow in the lower extremities, and normal alignment of the lumbar spine were restored, associated with partial recovery in the neurological status of the lower extremities.

Conclusion: The possibility of abdominal aortic rupture associated with lumbar spine fracture should always be considered in blunt force trauma. Endovascular stent-graft repair techniques, including the CERAB method, are a valid method for treating these patients. Vascular repair needs to be followed by early spinal stabilization to further diminish mortality and complications rate.

Keywords: spine injury, spine dislocation, traumatic aortic dissection, CERAB

INTRODUCTION

We present a case of traumatic dislocation of the L4 vertebra, associated with perforation of the small intestine and dissection of the infrarenal aorta. Furthermore, we describe our experiences with the surgical treatment of this complicated injury.

CASE STUDY

A 39 years old woman was transferred to our

Emergency Department after initial resuscitation in another hospital. She was injured the same evening in a car accident as a passenger, restrained by a seat-belt. On initial physical examination she demonstrated normal consciousness (GCS 15), painful left shoulder, thorax and abdomen, with haematoma consistent with seat-belt injury, and total paraplegia below L1 level. A polytrauma-protocol computed tomography, consisting of a native CT-scan of the head and cervical spine, followed by contrast-enhanced CT-scan of chest, abdomen and pelvis, revealed: perforation of small intestine with pneumoperitoneum, dissection of infrarenal aorta with retroperitoneal haematoma, and dislocation of L4 vertebra (traumatic spondylolisthesis grade 5, i.e. spondyloptosis) (Fig.1).

The patient was immediately taken to OR, where emergency laparotomy was performed. Multiple contusions and lacerations of the small intestine were found, and resection with T-T anastomosis was done. Following short stabilization of the patient in the ICU, she was again transported to the OR, where aortic injury was treated by Covered Endovascular Reconstruction of the Aortic Bifurcation technique (CERAB) through bilateral transfemoral approach (Fig.2). After stent graft position and patency check, the patient was turned in a prone position and lumbosacral spine was approached through standard midline incision. Transpedicular screws were inserted in L3, L4, L5, and S1 vertebrae. Screws were connected with longitudinal rods, and with limited distraction, full reposition of dislocation was accomplished (Fig.3). Laminectomies of L4 and L5 vertebrae and exploration of the spinal canal followed. Multiple dural lacerations and avulsions of cauda equina nerve roots were encountered. After repositioning of neural structures in the dural sac, dura was reconstructed with polyester urethane patch and monofilament sutures.

In postoperative period, the patient went through remarkable recovery. Normal function of the gastrointestinal tract was restored. Control doppler-sonography verified bilateral normal patency of AFC, AFS, AP, ATP, and ADP, regular three-phase flow

¹Department of Surgery, University Hospital Centre Zagreb, Zagreb, Croatia

²Department of Diagnostic and Interventional Radiology, Zagreb University Hospital Centre, Zagreb, Croatia

Corresponding author: Tihomir Banić, Department of Surgery, University Hospital Centre Zagreb, Kišpatičeva 12, Zagreb, Croatia

e-mail: tihomir.banic@gmail.com

DOI: 10.5281/zenodo.14009653

spectrum and velocity, without haemodynamic irregularities. Wound on the back healed normally, without signs of CSF leakage. Control radiography showed normal alignment of lumbar spine and good position of pedicular screws. Gradually, neurological status of lower extremities also improved: at the two-weeks' time after injury, when she was released from the hospital, the patient could demonstrate active flexion in the right hip and active extension in the right knee.

DISCUSSION

Severe spinal injuries occur in around 10% of polytraumatized patients [1]. Majority of these are caused by accidental falls (58.9%) and traffic accidents (20.9%) [2]. However, a section of spine which is the most often affected by trauma is located between T10 and L2 segments – an area known as the thoracolumbar junction [3]. The thoracic spine is relatively rigid due to coronal orientation of its facet joints and to bilateral costovertebral attachments. Conversely, sagittally oriented facets and lack of additional stabilization by thoracic cage, enable a considerably higher degree of motion in lumbar spine. The transitional zone between these two areas is a site of accumulation of kinetic energy transferred by trauma to other sections of spine, which makes the thoracolumbar junction particularly vulnerable to injury [4].

In this paper we present a patient who, unusually, suffered injury in L4-L5 level. We speculate this to be associated with seat-belt restraintment, which presumably acted as a fulcrum in flexion-extension movement of body during impact.

Spinal cord injury (SCI) is present in 26% of patients with thoracolumbar spine fracture [5]. Patients with lesion above the conus predominantly have symptoms of upper motor neuron dysfunction. Injuries below the conus characteristically cause lower motor neuron function deficit [3].

Our patient presented herself primarily with signs of lower motor neuron lesion. This was caused by avulsion and entrapment of cauda equina nerve roots, which was intraoperatively verified. Neural structures were decompressed and repositioned in the dural sac. The dura was reconstructed with polyesterurethane patch and non-absorbable monofilament sutures.

The role of timing of surgery in long-term neurological recovery of patients with SCI remains unclear [6-8]. However, most studies agree that early surgery (typically within 72 hours of injury) is associated with significantly less complications and with shorter duration of hospitalization [9-11].

Our patient was transferred to our Emergency Department approximately four hours after injury. The first surgical procedure was initiated 30 minutes later.

All surgical interventions were completed within 24 hours of injury, therefore, we met the criteria for early surgery.

Intraabdominal injuries are present in 7.6% of patients with thoracolumbar fractures after blunt force trauma [5]. However, this percentage is predictably much higher in more severe types of fractures – up to 38.7% in flexion-distraction injuries [12-15].

In our case, three perforations of the small intestine were found during exploration of the abdominal cavity. They were treated with resection and T-T anastomosis. No lesions of solid organs were encountered.

Aortic rupture has a very low occurrence in non-penetrating abdominal trauma with fracture of thoracolumbar spine [16]. However, it is a very dangerous condition, with a total mortality rate of 90%, and estimated prehospital mortality of 85% [17-20].

Furthermore, traumatic aortic rupture is usually located on the level of isthmus – just distal to the origin of left subclavian artery [19]. Ruptures of subdiaphragmatic/abdominal aorta associated with a spinal fracture, as seen in our patient, are extremely rare, with only several cases described in literature [16, 17, 21-24].

Open surgery was traditionally considered a golden standard in treatment of aortic ruptures. However, its grave complications (risk of renal failure and neurological deficit, pulmonary complications, prolonged intubation and mechanical ventilation) have encouraged development of endovascular repair technique [19]. Studies have demonstrated decrease of mortality rate from 35-45% in open surgery to 9% in endovascular stent-graft repair of thoracic aortic ruptures [24-27]. Further improvement in treatment of aortic bifurcation pathologies have been achieved by development of Covered Endovascular Reconstruction of the Aortic Bifurcation (CERAB) technique [28]. The goal of this procedure is to improve stent patency rate by imitating physiologic and anatomical characteristics of aortic bifurcation [29-30].

In our patient, we successfully repaired abdominal aortic rupture by using the CERAB method. Dimensions of aortic stent graft were 14x49 mm, and of iliac grafts 8x57 mm on right side, and 7x57 mm on left side. Postoperative doppler-sonography has shown normal patency of grafts with regular hemodynamic flow parameters.

CONCLUSION

Despite its relatively rare incidence, the possibility of abdominal aortic rupture associated with lumbar spine fracture should always be considered in blunt force trauma. It is extremely high mortality rate can be reduced by urgent and precise diagnostic work-up, primarily in the form of contrast-enhanced whole-body CT scan,

and prompt surgical treatment. Endovascular stent-graft repair techniques, including the CERAB method, are burdened with less complications than classic open surgery. Vascular repair needs to be followed by early spinal stabilisation, as it further diminishes mortality, complications rate, and duration of hospitalization.

REFERENCES

- Hasler RM, Exadaktylos AK, Bouamra O, Benneker LM, Clancy M, Sieber R, Zimmermann H, Lecky F. Epidemiology and predictors of spinal injury in adult major trauma patients: European cohort study. *Eur Spine J*. 2011 Dec;20(12):2174-80.
- Wang H, Zhang Y, Xiang Q, Wang X, Li C, Xiong H, Zhou Y. Epidemiology of traumatic spinal fractures: experience from medical university-affiliated hospitals in Chongqing, China, 2001-2010. *J Neurosurg Spine*. 2012 Nov;17(5):459-68.
- Fernández-de Thomas RJ, De Jesus O. Thoracolumbar Spine Fracture. 2021 Aug 30. In: *StatPearls [Internet]*. Treasure Island (FL): StatPearls Publishing; 2022 Jan--.
- Shores A. Spinal trauma. Pathophysiology and management of traumatic spinal injuries. *Vet Clin North Am Small Anim Pract*. 1992 Jul;22(4):859-88.
- Katsuura Y, Osborn JM, Cason GW. The epidemiology of thoracolumbar trauma: A meta-analysis. *J Orthop*. 2016 Jul 21;13(4):383-8. doi: 10.1016/j.jor.2016.06.019.
- Aarabi B, Akhtar-Danesh N, Chryssikos T, Shanmuganathan K, Schwartzbauer GT, Simard JM, Olexa J, Sansur CA, Crandall KM, Mushlin H, Kole MJ, Le EJ, Wessell AP, Pratt N, Cannarsa G, Lomangino C, Scarboro M, Aresco C, Oliver J, Caffes N, Carbine S, Mori K. Efficacy of Ultra-Early (< 12 h), Early (12-24 h), and Late (>24-138.5 h) Surgery with Magnetic Resonance Imaging-Confirmed Decompression in American Spinal Injury Association Impairment Scale Grades A, B, and C Cervical Spinal Cord Injury. *J Neurotrauma*. 2020 Feb 1;37(3):448-457.
- Muratore M, Allasia S, Viglierchio P, Abbate M, Aleotti S, Masse A, Bistolfi A. Surgical treatment of traumatic thoracolumbar fractures: a retrospective review of 101 cases. *Musculoskelet Surg*. 2021 Apr;105(1):49-59.
- Fehlings MG, Vaccaro A, Wilson JR, Singh A, W Cadotte D, Harrop JS, Aarabi B, Shaffrey C, Dvorak M, Fisher C, Arnold P, Massicotte EM, Lewis S, Rampersaud R. Early versus delayed decompression for traumatic cervical spinal cord injury: results of the Surgical Timing in Acute Spinal Cord Injury Study (STASCIS). *PLoS One*. 2012;7(2):e32037.
- Niedermeier SR, Khan SN. Polytrauma Patients With Associated Spine Fractures: An Assessment of Surgical Intervention on Patient Outcome. *Clin Spine Surg*. 2017 Feb;30(1):E38-E43.
- Chipman JG, Deuser WE, Beilman GJ. Early surgery for thoracolumbar spine injuries decreases complications. *J Trauma*. 2004 Jan;56(1):52-7.
- Carreon LY, Dimar JR. Early versus late stabilization of spine injuries: a systematic review. *Spine (Phila Pa 1976)*. 2011 May 15;36(11):E727-33.
- LeGay DA, Petrie DP, Alexander DI. Flexion-distraction injuries of the lumbar spine and associated abdominal trauma. *J Trauma*. 1990 Apr;30(4):436-44.
- Anderson PA, Henley MB, Rivara FP, Maier RV. Flexion distraction and chance injuries to the thoracolumbar spine. *J Orthop Trauma*. 1991;5(2):153-60.
- Tyroch AH, McGuire EL, McLean SF, Kozar RA, Gates KA, Kaups KL, Cook C, Cowgill SM, Griswold JA, Sue LA, Craun ML, Price J. The association between Chance fractures and intra-abdominal injuries revisited: a multicenter review. *Am Surg*. 2005 May;71(5):434-8.
- Chapman JR, Agel J, Jurkovich GJ, Bellabarba C. Thoracolumbar flexion-distraction injuries: associated morbidity and neurological outcomes. *Spine (Phila Pa 1976)*. 2008 Mar 15;33(6):648-57.
- Domenicucci M, Ramieri A, Landi A, Melone AG, Raco A, Ruggiero M, Speciale F. Blunt abdominal aortic disruption (BAAD) in shear fracture of the adult thoraco-lumbar spine: case report and literature review. *Eur Spine J*. 2011 Jul;20 Suppl 2(Suppl 2):S314-9.
- Santoro G, Ramieri A, Chiarella V, Vigliotta M, & Domenicucci M. (2018). Thoraco-lumbar fractures with blunt traumatic aortic injury in adult patients: correlations and management. *European Spine Journal*, 27(S2), 248-257.
- Dajee H, Richardson IW, Iype MO. Seat belt aorta: acute dissection and thrombosis of the abdominal aorta. *Surgery*. 1979 Mar;85(3):263-7.
- Leong Tan GW, Pek CH, Wong D, Punamiya S, Chiu MT, Appasamy V, Chia KH, Lee CW. Management of blunt traumatic thoracic aorta injuries with endovascular stent-grafts in a tertiary hospital in an urban Asian city. *Ann Vasc Surg*. 2011 Jul;25(5):605-11.
- Parmley LF, Mattingly TW, Manion WC, Jahnke EJ Jr. Nonpenetrating traumatic injury of the aorta. *Circulation*. 1958 Jun;17(6):1086-101.
- Chock, M. M., Aho, J., Naik, N., Clarke, M., Heller, S., & Oderich, G. S. (2014). Endovascular treatment of distal thoracic aortic transection associated with severe thoracolumbar spinal fracture. *Vascular*, 23(5), 550-552.
- Murakami R, Tajima H, Ichikawa K, Kobayashi Y, Sugizaki K, Yamamoto K, Kurokawa A, Kumazaki T. Acute traumatic injury of the distal descending aorta associated with thoracic spine injury. *Eur Radiol*. 1998;8(1):60-2.
- Stambough JL, Ferree BA, Fowl RJ. Aortic injuries in thoracolumbar spine fracture-dislocations: report of three cases. *J Orthop Trauma*. 1989;3(3):245-9.
- Kovari VZ, Pecs F, Cs Janvari M, Veres R. Initial experience with the treatment of concomitant aortic pseudoaneurysm and thoracolumbar spinal fracture: Case report. *Trauma Case Rep*. 2017 Nov 6;12:48-53. doi: 10.1016/j.tcr.2017.10.019.
- Khoynezhad A, Aizzadeh A, Donayre CE, Matsumoto A, Velazquez O, White R; RESCUE investigators. Results of a multicenter, prospective trial of thoracic endovascular aortic repair for blunt thoracic aortic injury (RESCUE trial). *J Vasc Surg*. 2013 Apr;57(4):899-905.e1.
- Fabian TC, Richardson JD, Croce MA, Smith JS Jr, Rodman G Jr, Kearney PA, Flynn W, Ney AL, Cone JB, Luchette FA, Wisner DH, Scholten DJ, Beaver BL, Conn AK, Coscia R, Hoyt DB, Morris JA Jr, Harviel JD, Peitzman AB, Bynoe RP, Diamond DL, Wall M, Gates JD, Asensio JA, Anderson BL, et al. Prospective study of blunt aortic injury: Multicenter Trial of the American Association for the Surgery of Trauma. *J Trauma*. 1997 Mar;42(3):374-80; discussion 380-3.
- Lee WA, Matsumura JS, Mitchell RS, Farber MA, Greenberg RK, Aizzadeh A, Murad MH, Fairman RM. Endovascular repair of traumatic thoracic aortic injury: clinical practice guidelines of the Society for Vascular Surgery. *J Vasc Surg*. 2011 Jan;53(1):187-92.
- Grimme FA, Goverde PC, Verbruggen PJ, Zeebregts CJ, Reijnen MM. Editor's Choice--First Results of the Covered Endovascular Reconstruction of the Aortic Bifurcation (CERAB) Technique for Aortoiliac Occlusive Disease. *Eur J Vasc Endovasc Surg*. 2015 Nov;50(5):638-47.

29. Mwipatayi BP, Thomas S, Wong J, Temple SE, Vijayan V, Jackson M, Burrows SA; Covered Versus Balloon Expandable Stent Trial (COBEST) Co-investigators. A comparison of covered vs bare expandable stents for the treatment of aortoiliac occlusive disease. *J Vasc Surg.* 2011 Dec;54(6):1561-70.
30. Groot Jebbink E, Holewijn S, Slump CH, Lardenoije JW, Reijnen MMPJ.

Systematic Review of Results of Kissing Stents in the Treatment of Aortoiliac Occlusive Disease. *Ann Vasc Surg.* 2017 Jul;42:328-336.

CONFLICT OF INTEREST:

The authors declare that there is no conflict of interest.

FIGURES

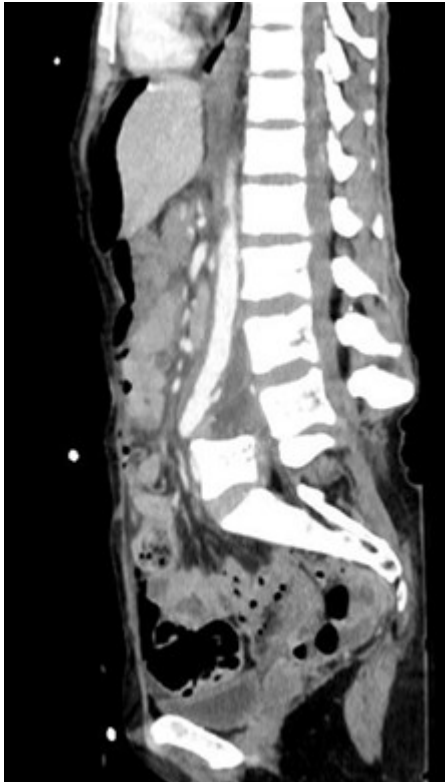


Figure 1. Preoperative polytrauma-protocol computed tomography

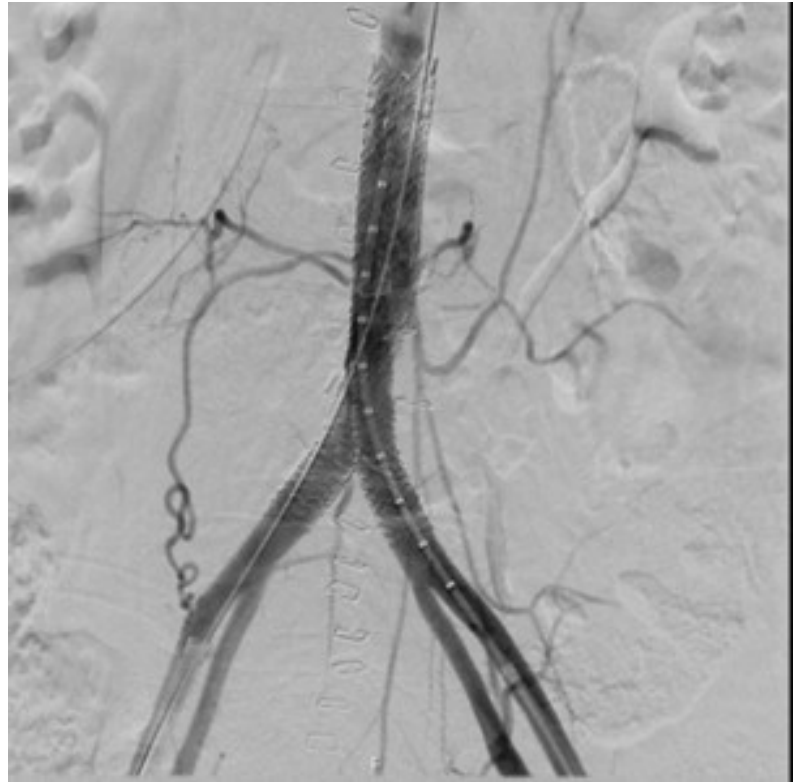

Figure 2. Repair of aortic dissection using CERAB technique

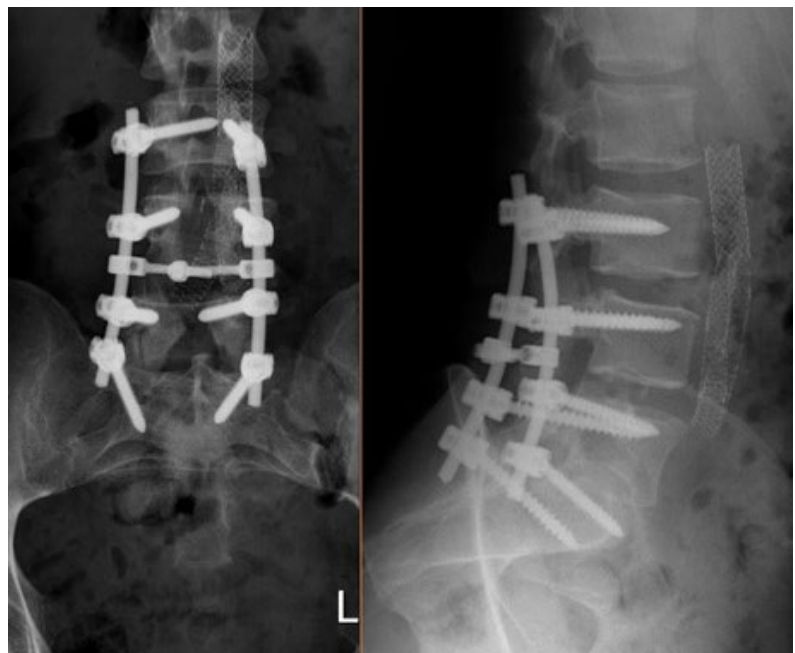

Figure 3. Surgical reduction and transpedicular fixation of L4 vertebral dislocation